

INTRA-RENAL ARTERIAL DOPPLER STUDY IN ACUTE RENAL OBSTRUCTION

Shivani Katal¹, Suvanya Mahajan², Pamposh Pandita³, Rajesh Sharma⁴

¹Radiodiagnosis Resident, Government Medical College, Jammu, J and K, India.

²Radiodiagnosis Resident, Government Medical College, Jammu, J and K, India.

³Radiodiagnosis Resident, Government Medical College, Jammu, J and K, India.

⁴Professor, Department of Radiodiagnosis, Government Medical College, Jammu, J and K, India.

Received : 03/09/2023
Received in revised form : 11/10/2023
Accepted : 25/10/2023

Keywords:
Urolithiasis, Doppler ultrasonography, Renal Doppler, acute renal obstruction, resistive index.

Corresponding Author:
Dr. Shivani Katal,
Email: katal96.js@gmail.com.

DOI: 10.47009/jamp.2023.5.5.137

Source of Support: Nil,
Conflict of Interest: None declared

Int J Acad Med Pharm
2023; 5 (5); 703-707



Abstract

Background: Urolithiasis is a prevalent global issue causing acute renal obstruction. Timely and accurate diagnosis is crucial for effective management. In this context, the use of intra-renal arterial Doppler study has emerged as a promising non-invasive diagnostic tool. This study investigates its utility in acute renal obstruction cases. **Materials and Methods:** In 52 patients with renal colic, obstructed and unobstructed contralateral kidneys were evaluated with doppler ultrasonography. Mean resistive indices and differences in resistive indices (Δ RI) were calculated. **Results:** Higher mean Resistivity Index (RI) was observed in obstructed kidneys (mean: 0.70 ± 0.040) than in non-obstructed kidneys (mean: 0.59 ± 0.042). RI was relatively higher in obstructed kidneys in all the cases (p- Value 0.00008). The difference in RI between obstructed and unobstructed kidneys (Δ RI) was 0.10 ± 0.04 . The study revealed that Doppler ultrasonography, using discriminatory RI values (≥ 0.70) and Δ RI (≥ 0.08) thresholds, showed promising sensitivity (86.54%) and specificity (100%) for diagnosing acute renal obstruction. The sensitivity further increased to 90.38% with discriminatory RI value ≥ 0.7 and Δ RI (≥ 0.06). **Conclusion:** Combining anatomical and functional insights, Doppler ultrasonography offers accurate and timely diagnosis, reducing the need for ionizing radiation-based imaging, time and cost.

INTRODUCTION

The evaluation and management of acute renal obstruction, a potentially reversible condition frequently caused by urolithiasis, sometimes present crucial challenges in clinical practice. Timely and accurate diagnosis is pivotal to prevent irreversible renal damage and ensure appropriate therapeutic interventions.

The utilization of non-invasive imaging techniques gains paramount significance in this context.^[1] One such technique that has garnered increasing attention is intrarenal arterial Doppler ultrasonography.^[2] Intra-renal arterial Doppler study offers a unique insight into the hemodynamic alterations that occur within the kidneys during acute obstruction. Key parameters, such as the Resistive Index (RI), derived from the Doppler waveform can provide valuable information about the resistance to blood flow within the renal vasculature.^[3] An increased RI is indicative of elevated vascular resistance, often observed in the presence of acute obstruction. RI also correlates with the degree of obstruction.^[4] Observing these dynamic alterations, clinicians can make informed decisions

about patient management and potential interventions.^[5]

The technique's non-invasiveness, lack of radiation, and real-time monitoring capabilities further underscore its significance in diagnosing and assessing renal obstruction, contributing to improved patient care and outcomes,^[6] especially in situations where exposure to radiation is contraindicated, such as in pregnant females and pediatric population.

The relative accessibility and cost-effectiveness of Doppler ultrasonography further enhance its potential as an imperative diagnostic modality for acute renal obstruction.^[7]

MATERIALS AND METHODS

The present study was carried out at the Postgraduate Department of Radiodiagnosis in Government Medical College, Jammu. This observational cross-sectional study spanned a year from November 2021 to October 2022 and was approved by the Institutional Ethics Committee of the hospital.

A total of 52 patients were enrolled, following specific inclusion and exclusion criteria. Inclusion

criteria encompassed adults of both genders, aged between 18 and 60 years, who presented with acute unilateral flank pain of radiating or non-radiating nature, within 48 hours of pain onset. Exclusion criteria consisted of patients presenting after 48 hours of pain onset, bilateral flank pain, absence of obstruction evidence on imaging, known cases of urolithiasis or chronic renal obstruction, known renal parenchymal diseases or anomalies, extremes of age groups (under 18 or above 60 years), and pregnant females.

The study first employed Gray Scale Ultrasonography using a curvilinear low-frequency transducer to examine patients. The presence and degree of hydronephrosis were assessed on the symptomatic side, and possible obstructing calculi were sought in the renal pelvis, pelvi-ureteral junction, upper ureter, and if no definite stone was visualized, further exploration was done through the bladder, vesicoureteral junction and tracing the ureter till iliac crossing. Graded compression with insinuation was used if needed.

Doppler waveforms were recorded with appropriate adjustments (PRF, gain, depth, filter wall and Doppler frequency) from intrarenal (interlobar/arcuate) arteries at the upper, middle, and lower poles along borders of medullary pyramids, in both the obstructed and contralateral non-obstructed kidney. The difference of RI between both sides was also calculated (Δ RI). In patients with non-confirmatory ultrasonography, plain abdomen KUB radiograph or non-enhanced CT abdomen-pelvis was performed to seek obstructing calculus.

RESULTS

The study group comprised 52 patients, including 15 females and 37 males, with ages ranging from 19 to 58 years. The primary clinical manifestation was flank pain, often accompanied by other symptoms like nausea, vomiting, urinary urgency, frequency, dysuria, burning micturition, and hematuria. Majority of the patients presented within 12 hours of the onset of unilateral flank pain (Table 1). Out of the total patients, only 2 individuals sought medical attention beyond 36 hours but within 48 hours of pain onset.

Among the patients, 65% reported pain radiating to the ipsilateral lower abdomen or groin region.

Grey scale ultrasound identified dilated renal collecting systems in most cases (50 out of 52). Grade II hydronephrosis was the most common (71%), followed by grade I (19%), grade III (6%), and no significant dilatation (4%)(Table-2a,b). While most cases were successfully identified by ultrasound, a small portion required additional imaging modalities for confirmation namely abdominal KUB radiography (6%), or CT KUB(4%).

Analyzing the site of obstruction highlighted a higher occurrence at the distal ureter (38%), followed by proximal ureter (31%), vesico-ureteric junction (21%), mid ureter (6%), and pelvi-ureteric junction (4%)(Table-3).

The size of the obstructing calculus was also investigated, with 73% falling in the 5.1-10.0 mm range, 17% between 10.1-15.0 mm, 8% within 0-5.0 mm, and only 2% exceeding 15.0 mm.

Doppler Sonography was performed in all cases. The crucial finding in the study pertained to the renal Resistive Indices (RI). In obstructed kidneys, the mean RI was 0.70 ± 0.040 , whereas in non-obstructed kidneys, it was 0.59 ± 0.042 (Figure-1,2). The difference in RI between obstructed and non-obstructed kidneys (Δ RI) was 0.10 ± 0.040 . These results demonstrated a higher mean RI in obstructed kidneys compared to non-obstructed kidneys, indicating increased resistance to blood flow in cases of obstruction. This difference was statistically significant (p-Value 0.00008). It was observed that patients presenting within 6 hours of symptom onset displayed a lower propensity for elevated RI or Δ RI values (64.7%) compared to those presenting later. The grade of pelvi-calyceal system dilatation also influenced RI values, with higher grades correlating to increased RI values.

In our study of 52 patients, utilizing a discriminatory RI value ≥ 0.70 or Δ RI ≥ 0.08 , we observed a sensitivity of 86.54% and specificity of 100%. Sensitivity of 82.69% was observed using discriminatory RI value > 0.70 with Δ RI ≥ 0.08 and the sensitivity further increased (90.38%) when discriminatory RI value ≥ 0.70 and Δ RI ≥ 0.06 were taken into account. When only RI > 0.7 was taken into consideration, sensitivity of only 46.15% was observed.

Table 1: Resistive indices variation with duration of obstruction

DURATION	NO. OF PATIENTS	PATIENTS WITH RI> 0.70	PATIENTS WITH RI \geq 0.08	RI>0.70 OR Δ RI \geq 0.08
<6HRS	17	5	8	11 (64.7%)
7-12 HRS	19	11	16	17 (89.4%)
13 TO 24 HRS	8	3	7	7 (87.5%)
25 TO 48 HRS	8	5	7	8 (100%)

Table 2a: Resistive indices variation with grade of HDN

GRADE OF PCS DILATATION	NUMBER OF PATIENTS	NO. OF PATIENTS WITH RI>0.70 OR Δ RI \geq 0.08
I	10	9 (90%)
II	37	30(81%)
III	3	3(100%)

Table 2b: Grey scale findings in obstructed kidneys

GRADE OF HDN/HDUN	NO. OF PATIENTS	PERCENTAGE OF PATIENTS
ABSENT	2	4
GRADE I	10	19
GRADE II	37	71
GRADE III	3	6
GRADE IV	0	0
TOTAL	52	100

Table 3: Site of obstruction

LEVEL OF OBSTRUCTION	NO. OF PATIENTS	PERCENTAGE OF PATIENTS
PELVI-URETERIC JUNCTION	2	4
PROXIMAL URETER	16	31
MID URETER	3	6
DISTAL URETER	20	38
VESICO-URETERIC JUNCTION	11	21
TOTAL	52	100

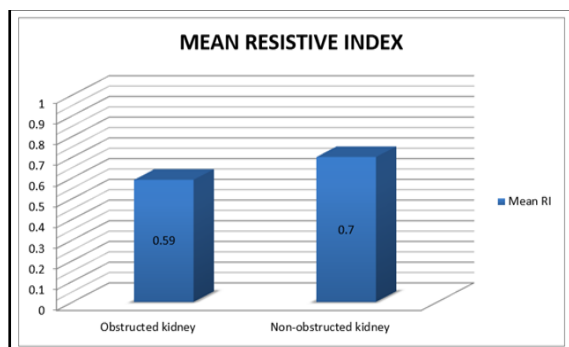


Figure 1: Mean resistive indices in obstructed and unobstructed kidneys

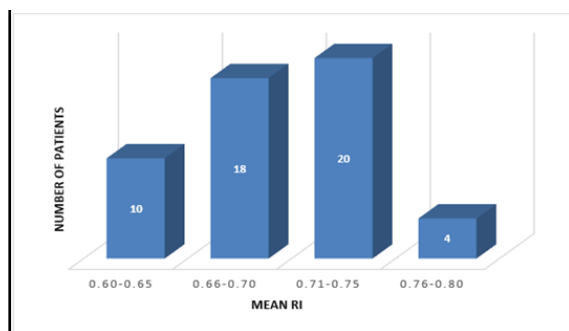


Figure 2: Distribution of resistive indices values

DISCUSSION

Despite its promising prospects, research regarding the application of intrarenal arterial Doppler study in acute renal obstruction is still evolving. The role of Doppler Ultrasonography has been a subject of debate, as some studies have reported lower sensitivities compared to more invasive techniques. In our study of 52 patients, sensitivity of 86.54% and specificity of 100% was observed by using discriminatory RI value of ≥ 0.70 or $\Delta RI \geq 0.08$ for acute renal obstruction.

Similar results were found in study by Saboo SS et al., in which sensitivity and specificity obtained were 95% and 100% respectively taking discriminatory RI value ≥ 0.70 and $\Delta RI \geq 0.06$ into consideration. Our results also correlate well with many studies reported earlier like Apoku IN et al., with sensitivity and

specificity: 86.7% and 90% respectively,^[10] Gul H et al,^[11] with sensitivity: 87% and Miletic D et al,^[12] with sensitivity and specificity: 95% and 100% respectively.

Doppler study stands as an invaluable asset in the armamentarium of medical professionals managing acute renal obstruction.^[13] The obstruction-induced changes in the vascular dynamics, mediated by vasoactive factors such as thromboxane A₂, angiotensin II, endothelin, and nitric oxide, lead to modifications in renal blood flow and vascular resistance.^[14,15,16] These changes can be assessed and quantified through Doppler ultrasonography, providing valuable diagnostic information as well as monitoring changes in renal blood flow over time.^[17] High-frequency sound waves bounce off red blood cells within the renal arteries and the returning sound waves, altered by the movement of blood, are then analyzed to determine the speed and direction of blood flow.^[18] The factors affecting Resistive Indices, such as the duration of symptoms, site of obstruction, PCS dilatation, and size of the calculus, provides valuable insights into the complexity of renal hemodynamics during obstruction. Moreover, its ability to differentiate obstructive from non-obstructive pelvicalyceal dilatation holds significance in avoiding unnecessary interventions.^[19]

Factors Affecting Resistivity Indices

1. Duration of symptoms (Table 1):

Patients presenting within 48 hrs after the onset of symptoms were included in this study. Those presenting within 6 hrs of onset showed least rise in RI than the rest (64.7% vs. 92.3%). Similar results were obtained in the study by Opdenakker L et al.^[20]

2. Site of obstruction (Table 3):

The site of obstruction was proximal (including pelvi-ureteric junction, proximal and mid ureter) in 21 (40%) cases and distal (including vesico-ureteric junction and distal most ureter) in 31 (60%) cases. A small difference of mean RI was observed depending on the level of obstruction with relative higher values in case of proximal obstruction (proximal= 0.71 vs. distal=0.70).

However in the study conducted by Viyannan M et al., the results were contrary.^[8]

3. PCS dilatation on greyscale ultrasound (Table 2A, 2B)

PCS dilatation was observed in 50 (96.15 %) patients on grey scale ultrasonography, while it was absent in 2 (3.8%) patients. RI values were raised in either, unrelated to presence or absence and grade of hydronephrosis.

In patients with no PCS dilatation despite the obstruction, Doppler sonography was sensitive in diagnosing acute renal obstruction by showing a raised RI value (≥ 0.70).

4. Size of calculus

Average size of calculus in obstructed kidneys demonstrating positive Doppler findings was 8.1 mm. In obstructed kidneys which failed to demonstrate Doppler findings of obstruction, size of calculus was 7.7mm with majority of these patients presenting within 6 hours of onset (66.6%) supporting the findings by Opdenakker L et al., that duration of obstruction is more valuable than size of the calculus and Doppler findings maybe inconclusive when performed within 6 hours of obstruction.^[20]

Several factors can influence the accuracy and interpretability of Doppler findings.^[21] Patient characteristics such as obesity or body habitus can pose challenges in obtaining clear and reliable Doppler signals due to increased tissue depth and decreased acoustic windows.^[19] Additionally, patient positioning and cooperation play a pivotal role in obtaining accurate Doppler parameters. Patients with significant pain, discomfort, or agitation might exhibit variations in calculating hemodynamic parameters, potentially affecting Doppler measurements.^[22]

Technical factors including the experience and skill of the ultrasound operator can also impact the quality of Doppler images.^[23] Operator proficiency in identifying renal anatomy, adjusting Doppler settings, and accurately measuring parameters like Resistive Index (RI) is crucial to ensure reliable results. Vascular calcifications or atherosclerosis can create signal attenuation or distortion, potentially limiting the accuracy of flow velocity measurements.^[24] Recognizing and addressing these related factors is vital for optimizing the utility of intra-renal arterial Doppler study in acute renal obstruction. Mitigating these influences through appropriate patient selection, optimal positioning, and skilled ultrasound operation, diagnostic accuracy and clinical relevance of Doppler-derived information can be enhanced, decisively facilitating better decision-making and patient care.

CONCLUSION

Ultrasonography presents itself as a versatile, easily accessible, and radiation-free tool that offers insights into both anatomical changes and functional aspects of renal obstruction. While renal scintigraphy

remains the gold standard, Doppler ultrasonography has demonstrated its potential to provide accurate and timely diagnosis, especially when ionizing radiation exposure is a concern. The variability in sensitivity and specificity observed across various studies underscores the need for a comprehensive approach in interpreting Doppler results, considering the interplay of multiple contributing factors.

Acknowledgement

The researcher expresses a sense of deep gratitude towards superiors for consistently overseeing this project.

Conflicts of interest

None declared.

REFERENCES

1. Reddy CG, Chidambaram R. Role of Renal Resistive Index in Unilateral Acute Renal Obstruction, Diabetic and Hypertensive Nephropathy. *Annals of the Romanian Society for Cell Biology*. 2021;25(2):913-922.
2. Araki M, Park SJ, Dauerman HL, Uemura S, Kim JS, Di Mario C et al. Optical coherence tomography in coronary atherosclerosis assessment and intervention. *Nature Reviews Cardiology*. 2022;19(10): 684-703.
3. Moses AA, Fernandez HE. Ultrasonography in Acute Kidney Injury. *POCUS J*. 2022;7:35-44.
4. Elsamea MHA, Badr AN, Ibrahim HM, Talaat EA. Renal arterial resistive index as a noninvasive biomarker of disease activity in lupus nephritis patients. *The Egyptian Rheumatologist*. 2022;44(3):239-244.
5. Asif M, Baba HS, Anjum MN. Correlation of resistive index of main renal artery and inter-lobar artery with degree of hydronephrosis. *The Professional Medical Journal*. 2022;29(03):407-414.
6. Eryildirim B, Şahan A, Türkoğlu Ö, Tuncer M, Kavukoğlu Ö, Şimsek B et al. Non-invasive evaluation of obstruction after ureteroscopic stone removal: Role of renal resistive index assessment. *Arch Ital Urol Androl*. 2020; 92(3).
7. Cholerzyńska H, Zasada W, Michalak H, Miedziaszczyk M, Oko A, Idasiak-Piechocka I. Urgent Implantation of Peritoneal Dialysis Catheter in Chronic Kidney Disease and Acute Kidney Injury—A Review. *Journal of Clinical Medicine*. 2023;12(15): 5079.
8. Viyannan M, Kappumughath MS, Nagappan E, Balalakshmoji D. Doppler sonographic evaluation of resistive index of intra-renal arteries in acute ureteric obstruction. *Journal of Ultrasound*. 2021;24: 481-488.
9. Saboo SS, Soni SS, Saboo SH, Chinapuvvula NR, Kaza S. Doppler sonography in acute renal obstruction. *IJRIE*. 2007;17(3):188-192.
10. Apoku IN, Ayoola, Salako AA, Idowu BM. Ultrasound evaluation of obstructive uropathy and its hemodynamic responses in southwest Nigeria. *Int Braz J Urol* 2015;41(3):556-61.
11. Gul H, Habib I, Roghani IS. Diagnostic accuracy of renal arterial resistive index (RI) in acute renal colic. *KJMS*. 2014;7(1):92-95.
12. Miletic D, Fuckar Z, Sustic A, Mozetic V, Smokvina A, Stancic M. Resistance and pulsatility indices in acute renal obstruction. *J Clin Ultrasound* 1998;26(2):79-84.
13. Hester SC, Kuriakose M, Nguyen CD, Mallidi S. Role of ultrasound and photoacoustic imaging in photodynamic therapy for cancer. *Photochemistry and Photobiology*. 2020;96(2):260-279.
14. Johnson JL, Adkins D, Chauvin S. A review of the quality indicators of rigor in qualitative research. *American journal of pharmaceutical education*. 2020;84(1) :7120.
15. Umar A, Atabo S. A review of imaging techniques in scientific research/clinical diagnosis. *MOJ AnatPhysiol*. 2019;6(5):175-83.
16. Dahmarde H, Fazeli F. Should renal resistive index be considered as a routine predictor in newly diagnosed acute

- hydronephrosis in patients with unilateral renal colic?. *Medical perspectives J.* 2022;(3):72-78.
17. Sivan S, Vincenzi P, Shah R, Mahmoud M, Ortigosa-Goggins M. Renal allograft torsion, is sirolimus a culprit–Case series and review of literature. *Transplantation Reports.* 2021;6(4):100087.
 18. Hennink M, Kaiser BN. Sample sizes for saturation in qualitative research: A systematic review of empirical tests. *Soc Sci Med.* 2022;292:114523.
 19. Wijntjes J, Alfen NV. Muscle ultrasound: Present state and future opportunities. *Muscle & nerve.* 2021;63(4):455-466.
 20. Opdenakker L, Oyen R, Vervloessem I, Goethuys H, Baert AL, Baert LV et al. Acute obstruction of the renal collecting system: the intrarenal resistive index is a useful yet time-dependent parameter for diagnosis. *Eur Radiol* 1998;8:1429.
 21. Maryam T, Sattar A, Shafiq T, Imran A, Yasin S, Tahira S et al. Doppler Comparison of Resistive Index of Renal Artery in Obstructive and Non Obstructive Kidneys. *Journal of Health and Medical Sciences.* 2019;2(3).
 22. Evangelista GC, Dornelas LR, Cintra CC, Valente FL, Favarato ES, da Fonseca LA et al. Evaluating feline lower urinary tract disease: Doppler ultrasound of the kidneys. *Journal of Feline Medicine and Surgery.* 2023;25(1):1098612X221145477.
 23. Drudi FM, Cantisani V, Granata A, Angelini F, Messineo D, De Felice C et al. Multiparametric ultrasound in the evaluation of kidney disease in elderly. *Journal of ultrasound.* 2020;23:115-126.
 24. Qian X, Zhen J, Meng Q, Li L, Yan J. Intrarenal Doppler approaches in hemodynamics: A major application in critical care. *Front Physiol.* 2022;13:951307.